

20-month-old boy undergoes bypass

Risha Chittlangia | TNN

New Delhi: Recuperating in the cardiac care unit of Batra Hospital, 20-month-old Stawan Bijal Shah refuses his feed and cries for his mother. He is one of the youngest patients to undergo a coronary artery bypass surgery for a rare disease which damaged his heart.

When Stawan was just two months old, he was diagnosed with Kawasaki, which causes thickening and dilation of arteries resulting in severe blockage. "He developed rashes and had high fever which refused to subside despite medication. After nearly a month, a family doctor diagnosed him with Kawasaki. With medication we were able to control the disease, but the damage was done," said Payal Shah, Stawan's mother.

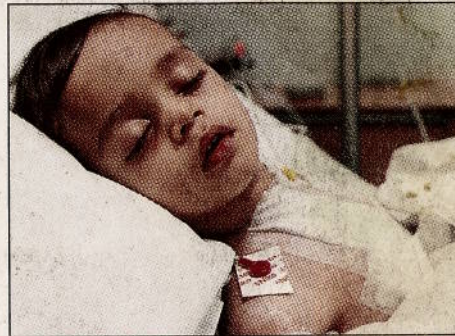
Doctors at Ahmedabad told the family that Stawan ran the risk of a cardiac arrest as his arteries had narrowed, but ruled out surgery as he was too small. Regular monitoring of his heart followed. "We had to be careful. Doctors had given aspirin to dilute his blood. But doctors said that the arteries had developed aneurysm with clots. We used to get an echocardiogram done every 90 days in order to keep a check on his hearts condition," said Bijal Shah, Stawan's father, a businessman.

A recent angiography revealed that one of Stawan's arteries had a 100% blockage and the other one was 80% blocked. "What causes Kawasaki is not known, but it is rare and results in inflammation of vessels. There was a high risk of a cardiac ar-

rest," said Dr Anil Bhan, head of the cardiac unit at Batra Hospital.

Despite several complicated factors like the size of the arteries, which is 1 mm in diameter in such small children, doctors decided to operate on Stawan. On May 25, Stawan underwent bypass surgery in which doctors not only gave him new grafts, but also completely revascularised his heart. "We joined the internal mammary artery with the left anterior descending, which was 100% blocked,

Yogesh Kumar



NEW LEASE OF LIFE: Stawan Bijal Shah suffered from a rare cardiac disease called Kawasaki

and took radial artery grafts from his left hand and fixed the blockage in the left circumference. We also removed the aneurysm in the right coronary artery," said Dr Bhan.

Stawan has smoothly crossed the crucial 24 hours period and doctors say that he is responding well to post-operative treatment. "We have kept him on medication, as he would feel the pain once the anaesthesia effect is gone. We have to be really careful. He has to be on medication for nearly two years so that the grafts are stable," said DR Rajesh Sharma, paediatric intensivist, Batra Hospital.

toireporter@timesgroup.com